

the same house as the patient — were asymptomatic and tested negative for SARS-CoV-2 on RT-PCR assay. Throat and nasopharyngeal swabs that were obtained from 10 other close contacts tested negative for SARS-CoV-2 on RT-PCR assay.

Wannarat A. Pongpirul, M.D.

Bamrasnaradura Infectious Diseases Institute
Nonthaburi, Thailand

Krit Pongpirul, M.D., Ph.D.

Chulalongkorn University
Bangkok, Thailand
doctorkrit@gmail.com

Anuttra C. Ratnarathon, M.D.

Wisit Prasithsirikul, M.D.

Bamrasnaradura Infectious Diseases Institute
Nonthaburi, Thailand

Disclosure forms provided by the authors are available with the full text of this letter at NEJM.org.

This letter was published on February 12, 2020, at NEJM.org.

1. Li Q, Guan X, Wu P, et al. Early transmission dynamics in Wuhan, China, of novel coronavirus-infected pneumonia. *N Engl J Med*. DOI: 10.1056/NEJMoa2001316.

2. Rothe C, Schunk M, Sothmann P, et al. Transmission of 2019-nCoV infection from an asymptomatic contact in Germany. *N Engl J Med* 2020;383:970-1.

DOI: 10.1056/NEJMc2001621

Reversal of TGF β 1-Driven Profibrotic State in Patients with Pulmonary Fibrosis

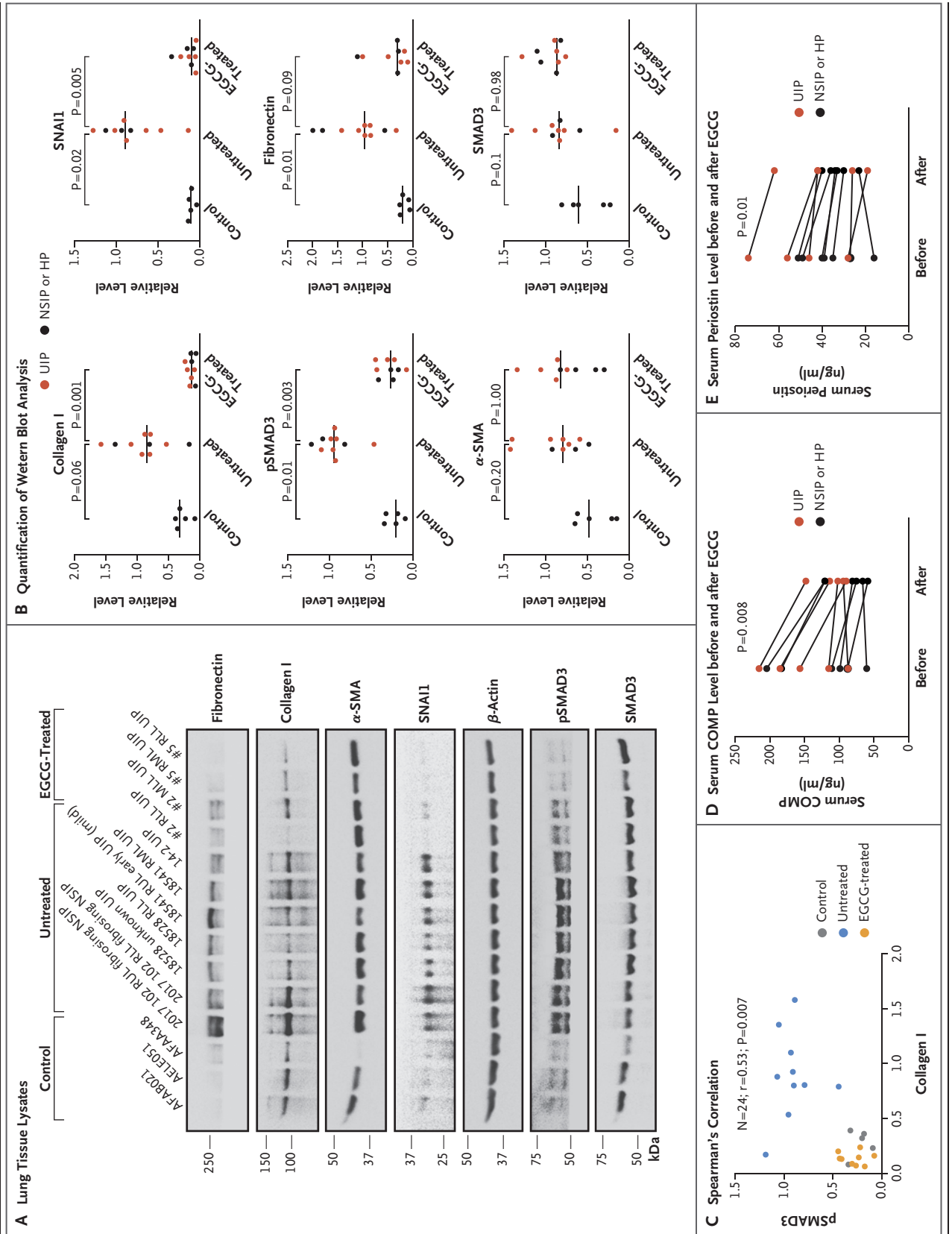
TO THE EDITOR: The multiple signaling roles of transforming growth factor beta 1 (TGF β 1) limit the development of global signaling inhibitors of the cytokine as therapeutic agents.^{1,2} Epigallocatechin gallate (EGCG), a commercially available food supplement, is a fibroblast-specific, irreversible inhibitor of both lysyl oxidase-like 2 (LOXL2) and TGF β receptors 1 and 2 (TGF β R1/2) kinase. Inhibition of LOXL2 generates the TGF β R1/2 kinase inhibitor,³ lowers cellular levels of phosphorylated SMAD2/3, and suppresses TGF β 1-induced matrix production with blockade

of collagen cross-linking. We tested the effect of oral EGCG treatment on lung tissues and serum samples obtained from 20 patients with pulmonary fibrosis who had presented to our interstitial lung disease clinic and were scheduled to undergo diagnostic lung biopsy. All the patients provided written informed consent.

In sequential order, half the patients were given capsules of EGCG (Teavigo) at a daily dose of 600 mg for 14 days before they underwent biopsy (treated group), and the other half did not receive the capsules (untreated group). We exam-

Figure 1 (facing page). Effect of EGCG on Biomarkers in Lung-Biopsy and Serum Samples from Patients with Pulmonary Fibrosis.

Panel A shows a Western blot analysis of lysates obtained from control lung tissue, from lung tissue obtained from untreated patients with pulmonary fibrosis, and from patients with pulmonary fibrosis who had received EGCG (all identified by their sample numbers), as analyzed for levels of fibronectin, collagen I, alpha smooth-muscle actin (α -SMA), SNAIL, β -actin, phosphorylated SMAD3 (pSMAD3), and total SMAD3. For each analysis, one of five representative gels is shown. Panel B shows the quantification of Western blot bands that had been normalized to β -actin and then to the reference sample (18541 RML UIP) on each gel. Multiple data points from biopsy samples of lung tissue obtained from the upper, middle, and lower lobes of each patient were averaged. Differences in protein levels across the three groups (5 control samples, 10 untreated samples, and 9 EGCG-treated samples) were tested for significance with the use of the exact Kruskal–Wallis distribution. Comparisons between the control group and the untreated group and between the untreated group and the EGCG-treated group were then performed with the use of exact Wilcoxon rank-sum testing with a Bonferroni correction. (Details are provided in Table S3 in the Supplementary Appendix.) Overall, of the patients who were included in the analyses, 60% had the fibrotic imaging pattern associated with usual interstitial pneumonitis (UIP), and the rest had nonspecific interstitial pneumonitis (NSIP) (30%) or hypersensitivity pneumonitis (HP) (10%). The horizontal lines indicate the mean values. Panel C shows the correlation between the pSMAD3 level and collagen I protein expression in 24 samples (Spearman's correlation, $r=0.53$; $P=0.007$). Data from control, untreated, and EGCG-treated patients are color-coded. Panels D and E show the results of enzyme-linked immunosorbent assays of serum cartilage oligomeric matrix protein (COMP) and periostin. Data from each patient before and after EGCG treatment were compared and analyzed with the use of the Wilcoxon signed-rank test (two-tailed).



ined tissue samples that were not required for the diagnostic studies to determine the extractable levels of validated tissue profibrotic markers³ and compared the levels in the two groups. Fragments from five normal lungs were also included in the study as a control. The 20 patients in the treated group and the untreated group had a mean forced vital capacity that was 70% of the predicted volume and a mean diffusing capacity for carbon monoxide that was 55% of the predicted volume. (The clinical and demographic characteristics of the patients are provided in the Supplementary Appendix, available with the full text of this letter at NEJM.org.)

Among the patients who received EGCG, tissue levels of extractable type I collagen, which was probably either poorly cross-linked or new collagen, were near the normal reference levels and were significantly lower than the levels in the untreated patients ($P=0.001$) (Fig. 1A and 1B). Likewise, in the treated patients, tissue levels of snail family transcriptional repressor 1 (SNAIL1) and phosphorylated SMAD3 were also significantly lower than those in the control cohort. There was no evidence of a between-group difference in levels of total SMAD3 or alpha smooth-muscle actin (α -SMA) among the various groups. The empirical correlation between the degree of reduction in collagen I protein and phosphorylated SMAD3 levels was positive, which was consistent with collagen expression driven by TGF β 1 signaling (Fig. 1C). We observed no evidence of correlation with collagen messenger RNAs (see the Supplementary Appendix), which suggests that the inhibition of LOXL2 collagen cross-linking may substantially contribute to reduced accumulation of collagen I.

Serum biomarkers indicative of progression of idiopathic pulmonary fibrosis (IPF) do not decrease in response to drugs that have been approved for use in such patients by the Food and Drug Administration.^{4,5} Surprisingly, during 14 days of EGCG treatment, we found decreased

amounts of two fibroblast-derived serum biomarkers, cartilage oligomeric matrix protein and periostin, which have been associated with IPF activity and prognosis,⁵ a finding that is consistent with an antifibrotic effect (Fig. 1D and 1E). Our data suggest that in patients with interstitial lung disease, EGCG treatment was associated with a reduction in fibrogenesis and thus may provide equipoise for the performance of a long-term, randomized clinical trial of EGCG involving patients with this condition.

Harold A. Chapman, M.D.

Ying Wei, M.D.

University of California, San Francisco
San Francisco, CA
hal.chapman@ucsf.edu

and Others

Drs. Chapman and Wei contributed equally to this letter.

A complete list of authors is available with the full text of this letter at NEJM.org.

Supported by a grant (to Dr. Chapman) from the Three Lakes Foundation and grants (R01 HL142265, to Dr. Chapman; R21 AG052744, to Dr. Le Saux; and K23 HL138190, to Dr. Oldham) from the National Institutes of Health. Authors who were employees of Pliant Therapeutics performed assays using their Nanostring equipment at no cost to the study.

Disclosure forms provided by the authors are available with the full text of this letter at NEJM.org.

1. Akhurst RJ, Hata A. Targeting the TGF β signalling pathway in disease. *Nat Rev Drug Discov* 2012;11:790-811.
2. Lacouture ME, Morris JC, Lawrence DP, et al. Cutaneous keratoacanthomas/squamous cell carcinomas associated with neutralization of transforming growth factor β by the monoclonal antibody fresolimumab (GC1008). *Cancer Immunol Immunother* 2015;64:437-46.
3. Wei Y, Kim TJ, Peng DH, et al. Fibroblast-specific inhibition of TGF- β 1 signaling attenuates lung and tumor fibrosis. *J Clin Invest* 2017;127:3675-88.
4. Maher TM, Stowasser S, Nishioka Y, et al. Biomarkers of extracellular matrix turnover in patients with idiopathic pulmonary fibrosis given nintedanib (INMARK study): a randomised, placebo-controlled study. *Lancet Respir Med* 2019;7:771-9.
5. Neighbors M, Cabanski CR, Ramalingam TR, et al. Prognostic and predictive biomarkers for patients with idiopathic pulmonary fibrosis treated with pirfenidone: post-hoc assessment of the CAPACITY and ASCEND trials. *Lancet Respir Med* 2018;6: 615-26.

DOI: 10.1056/NEJMc1915189

A Locally Transmitted Case of SARS-CoV-2 Infection in Taiwan

TO THE EDITOR: Since December 2019, an outbreak of infection with the novel coronavirus (SARS-CoV-2) has developed in Wuhan, China,

and has spread to several countries, typically by travelers returning from China.^{1,2} Of the 3 million Taiwanese persons who work in China,